

Artery/vein classification of blood vessel tree in retinal imaging

Joaquim de Moura¹, Jorge Novo¹, Marcos Ortega¹, Noelia Barreira¹ and Pablo Charlón²

¹*Departamento de Computación, Universidade da Coruña (Spain)*

²*Instituto Oftalmológico Victoria de Rojas (Spain)*

{joaquim.demoura, jnovo, mortega, nbarreira}@udc.es, pcharlon@sgoc.es

Keywords: Retinal imaging, vascular tree, segmentation, artery/vein classification.

Abstract: Alterations in the retinal microcirculation are signs of relevant diseases such as hypertension, arteriosclerosis, or diabetes. Specifically, arterial constriction and narrowing were associated with early stages of hypertension. Moreover, retinal vasculature abnormalities may be useful indicators for cerebrovascular and cardiovascular diseases. The Arterio-Venous Ratio (AVR), that measures the relation between arteries and veins, is one of the most referenced ways of quantifying the changes in the retinal vessel tree. Since these alterations affect differently arteries and veins, a precise characterization of both types of vessels is a key issue in the development of automatic diagnosis systems. In this work, we propose a methodology for the automatic vessel classification between arteries and veins in eye fundus images. The proposal was tested and validated with 19 near-infrared reflectance retinographies. The methodology provided satisfactory results, in a complex domain as is the retinal vessel tree identification and classification.

1 INTRODUCTION

The analysis of the eye fundus offers useful information about the status of the different structures the human visual system integrates, as happens with the analysis of the retinal vasculature, being considered a relevant way for the diagnosis and treatment of relevant pathologies. These exploratory processes allow clinicians to detect countless diseases that have a slow clinic evolution or do not show any symptomatic manifestation. These evaluations also permits the early identification of clinical conditions, facilitating the application of treatments and decreasing drastic consequences caused by the disease itself and its treatment.

The Optical Coherence Tomography (OCT) is a non-invasive exploratory method for the analysis of the eye fundus. Since its introduction in ophthalmology it became a basic tool for the detection and monitoring of several ocular illnesses (Brezinski, 2006). This technique allows us to get high-quality images that complement the information of classical retinographies with the depth information that the histological sections offer. These images enable the expert to make a quantitative and qualitative evaluation of the retinal morphology (Duker et al., 2014).

The retina is the only part of the human body where the specialists can analyze directly the vascular morphology and structure in a non-invasive way.

Hence, direct analysis of many injuries caused by ocular pathologies can be achieved, as is the case, for example, the diabetic retinopathy (DR). The DR is a diabetes mellitus complication, one of the principal causes of blindness in the world (Pascolini, 2011). It is considered the main cause of blindness in the working-age population (Whiting et al., 2011). The DR is caused mainly by the deterioration of the vascular structure that irrigates the retina, provoking leakage of fluid or blood. It causes the formation of blood clots in the retinal structure, deforming the represented image in the brain (Abu, 2008). Different studies demonstrated the association of the DR with the risk factors of other cardiovascular diseases as, for example, arteriosclerosis or hypertension (Wong, 2005).

Given the importance of this problematic, many efforts were done in the development of methodologies for the automatic measurement and analysis of the vasculature and its structural changes through, for instance, the Arterio-Venular-Ratio (AVR), i.e., a biomarker that analyzes the relation of the calibers of the arteries and veins. This measurement is commonly used by experts as a criterion prognosis in clinical settings mainly for DR detection but also for other conditions as hypertension. AVR, among others measurements, demonstrated that the analysis of the retinal vessel tree, through the analysis of the arteries and veins, is a crucial task. Computer-aided Diagnosis

(CAD) systems that automatically identifies and categorizes the arterio-venular tree can help and facilitate significantly the doctors' work.

In the literature we can find approaches that use different strategies to solve the analyzed problem. For example, (Joshi et al., 2014) used a methodology based on graphs to segment the vascular tree structure and then used color properties for the final artery/vein (A/V) classification. In (Cordero, 2011), the authors proposed a classification based on the analysis of the statistical features of the vascular segments. Another study (Kondermann et al., 2007) made use of an approximation based on pattern recognition due to artificial neural networks and Support Vector Machines (SVM) was also employed by (Yang et al., 2016) in a feature extraction and classification process. In (Dashtbozorg et al., 2014), the classification of a vessel segment as A/V is performed through the combination of the graph-based labeling results with a set of intensity features. (Vázquez et al., 2013), proposed a framework for the automatic classification A/V, but only for a few restricted set of coordinates that are posteriorly used in the calculation of the AVR biomarker.

In this work, we propose an entire methodology for the automatic extraction of the retinal vascular tree and its categorization into arteries and veins. The method extracts the vasculature and uses the k-means clustering algorithm with features from the vessel profiles to discriminate the arteries from veins.

We tested the methodology with near-infrared reflectance retinographies that are included in OCT scans. The method only employs the information of the retinographies as this proposal represents an initial stage that is planned to be complemented posteriorly with the analysis of the depth information that offer the histological sections that also are included by the OCT images.

This paper is organized as follows: section 2 is dedicated to describing the developed methodology. The experiments and results are included in section 3. Finally, section 4 shows the conclusion about the results obtained by our methodology.

2 METHODOLOGY

The proposed method receive, as input, a set of (OCT) images. Each image corresponds to consecutive histological sections representing the morphology of the retinal layers. These images are complemented with the corresponding near-infrared reflectance retinography of the eye fundus. Figure 1 shows the set of input images of our system.




Figure 1: Set of OCT images of the retina.

Firstly, the region of the retinography that corresponds with the histological sections is identified and extracted from the input image, as can be seen in Figure 2.

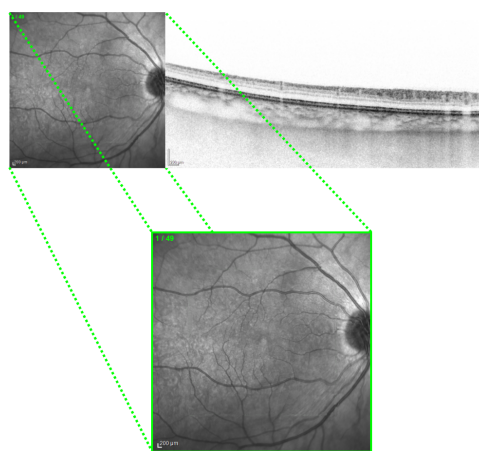


Figure 2: Extraction of the region of interest in the near-infrared reflectance retinography.

The proposed methodology, represented in Figure 3, is divided into three main steps: a first step, where the retinal vascular tree is extracted from the input image; a second step, where the location of the optic disc is identified; and finally, a third step, where the vessels are finally classified into arteries and veins. Each one of these steps is going to be discussed next.

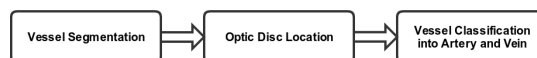

Figure 3: Main steps of the proposed methodology.

2.1 Vessel Segmentation

The first step in the classification process is the location of the blood vessels within the image. This step is necessary for a posterior extraction of the vascular features that are used in the posterior process of classification. For this purpose, we follow the methodology proposed in (Calvo et al., 2011), given its simplicity and for being a well-established technique. A

segmentation based on morphological operators is applied to obtain an initial representation of the vessels, as shown in Figure 4.

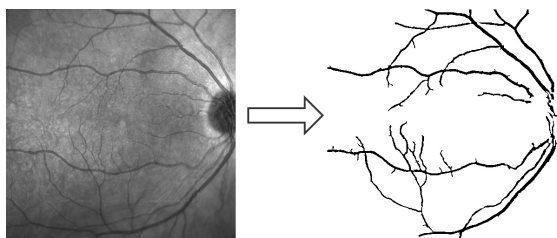


Figure 4: Segmentation of the vessel tree.

The vasculature centerline is then calculated to represent the vessels as a list of segments. For that purpose, the implemented strategy was inspired in the proposal of (Caderno et al., 2005). The vessels are located by means of the MLSEC-ST operator. The aim of this operator is the detection of tubular structures by the analysis of the structure tensor of the segmentation image. The output of this operator consists of the vessel centerlines of the vasculature, as Figure 5 represents.

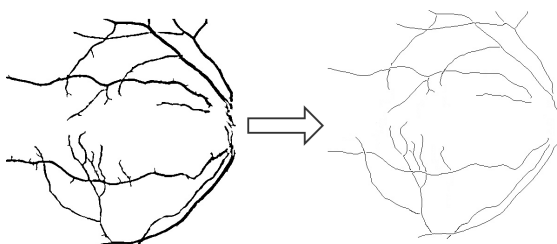


Figure 5: Vessel Centerline identification.

2.2 Optic Disc Location

The optic disc is a bright circular area formed by the optic nerve fibers. This is the region where the entire vessel tree appears in the eye fundus. The optic disc is a region with a clear bright contrast in comparison with the rest of the eye fundus. This can disturb the main characteristics of the vessels visualization, situation that can lead to vessel misclassifications. For that reason, the optic disc region is normally excluded for the analysis and characterization of the vasculature.

Next step is the identification and removal of the optic disc area. To achieve this, an algorithm based on the Hough transform (Blanco et al., 2006) was implemented. Firstly, the region of interest is identified using the Difference of Gaussian operator and the Blob detection method. Thus, we convolve the original image with two Gaussians filters at different scales and

calculate the difference between these convolutions. Finally, we combine these results with the Sobel operator to extract the optic disc from the remaining edges using the Hough transform. Figure 6 illustrates an example of the optic disc localization process.

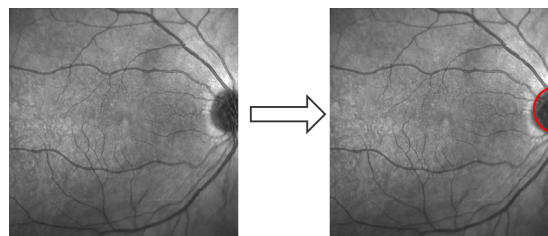


Figure 6: Optic disc localization.

The region of interest that is extracted in the near-infrared reflectance retinographies is normally focused on the macula. This may provoke that only a part of the optic disc appears in the image. However, the used strategy offers a robust behaviour, being able to locate the optic disc location, even in scenarios with only the partial inclusion of the optic disc.

Many times, not only the optic disc but also its contiguous region may include significant changes in brightness. Consequently, it is desirable to exclude a greater region to guarantee a correct categorization of the vasculature. This problem is solved by removing the circular area centered on the optic disc with a radius of $1.5R$, where R is the radius of the optic disc, as presented in Figure 7.

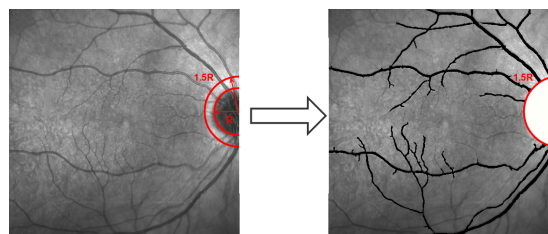


Figure 7: Process of removal of the optic disc region.

2.3 Artery/Vein Vessel Classification

The third step of the methodology aims the automatic classification of the retinal vasculature into arteries and veins. We designed a method consisting of three phases (see Figure 8).

2.3.1 Phase 1: Profile Extraction

Firstly, we obtain the profiles of the vessels that are posteriorly used to analyze the characteristics that are used in the process of the vessel classification. We

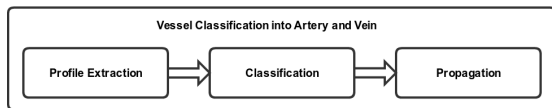


Figure 8: Phases of the vessel classification into arteries and veins step.

propose an approach based on the idea of the algorithm addressed in (Vázquez et al., 2013). This methodology was focused on a particular purpose, the calculation of the retinal AVR. For that reason, it was only applied in a specific set of coordinates used in the AVR calculation. We adapted this strategy to classify the entire vascular structure.

In this phase, we identify the vessel profiles to extract the feature vectors. For each point P of the centerline, we get four equidistant points P_i . We built the vessel profile as the perpendicular line that is limited by both vessel edges. The profiles are delimited by the edges of the vessel. Figure 9 illustrates an example of this approach.

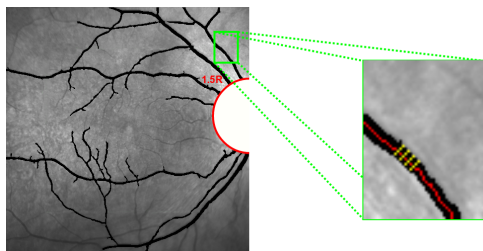


Figure 9: Profile extraction of a vessel. The four yellow lines perpendicular to the vessel centerline identify the vessel profile at the point.

2.3.2 Phase 2: A/V Classification

With the vessel profiles, we obtain the information used for the A/V classification through color profiles of the vessels and create the feature vectors.

Feature vectors are obtained by means of the methodology proposed by (Grisan and Ruggeri, 2003) which mainly consists of two components:

- $\mu(H)$ (from HSL color space).
- $\sigma^2(R)$ (from RGB color space).

The created feature vectors are the input of the classifiers. In this approach, due to its simplicity and computational efficiency, the K-means clustering technique was selected. This algorithm calculate the centroids for each one of the two clusters using as mean the euclidean distance between the cluster centroid and the value obtained in the feature vectors.

As result, each pixel of the vessel centerline is classified as belonging to an artery or vein. In Figure

10, we illustrate the result of the classification process over the centerline of a vessel. Red points represent arteries whereas blue points are veins. We can appreciate that there are points belonging to the same vascular segment but classified into different categories.

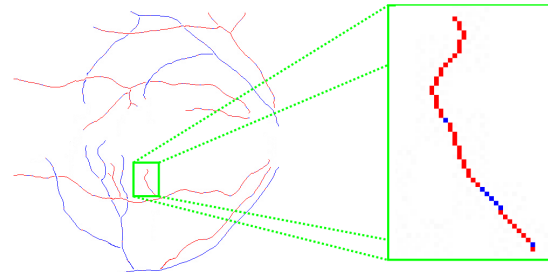


Figure 10: Results of the A/V classification over the centerline of a vessel. Red point, arteries; blue points, veins.

2.3.3 Phase 3: Propagation

Many times, points belonging to the same vascular segment are classified into different categories. For that reason, a post-processing to correct misclassifications was designed. To achieve this, a process of voting over the entire vessel is done. The category with higher number of votes is considered the one that represents the vessel. Then, the method propagates the results to all the pixels with the wrong class. Figure 11 shows the result of applying the method of propagation to correct misclassifications in the vascular segment.

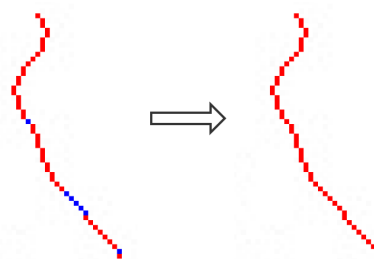


Figure 11: Propagation of the winning class by a majority vote of all points in the same vascular segment.

This process is repeated over the entire vessel tree, achieving the final vasculature extraction and A/V categorization. Figure 12 exposes an example of the output of the methodology illustrating the final result of the classification of the vessel tree into arteries and veins.

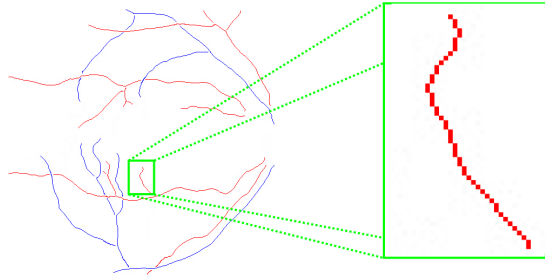


Figure 12: Final result of the methodology applied to the classification of vessels between arteries and veins.

3 EXPERIMENTAL RESULTS

The proposed method was tested with 19 patient scans that, in addition to the OCT histological sections, included the 19 near-infrared reflectance retinographies. The images were taken with a confocal scanning laser ophthalmoscope, a CIRRUSTM HD-OCT-Carl Zeiss Meditec. The scans are centered in the macula, from both left and right eyes of healthy patients, and with a resolution of 1520×496 pixels. The blood vessels have been manually classified by an expert clinician.

We have randomly selected 5 patient scans to develop and train the algorithm and the remaining 14 as the validation set. The classification results achieved by our algorithm on the validation set were compared to the manual labeling medical experts. A total of 14,745 categorized points from 405 vascular segments were analyzed from the validation set.

Firstly, we analyze the performance of the method in the entire vessel points. This analysis was made before propagations phase to measure the robustness of the A/V classification in individual vessel coordinates. We evaluated the accuracy of the proposed method using three metrics: accuracy, sensitivity and specificity. Sensitivity measures the proportion of actual positives (arteries, in our case) that are correctly identified whereas specificity measures the proportion of negatives (veins in our case) that are classified adequately. Table 1 presents the confusion matrix of our system in comparison with the labeling of the expert clinician. Moreover, Table 2 summarises the results obtained for the classification between arteries and veins in terms of accuracy, sensitivity and specificity over all vessel coordinates.

We also calculated, in Table 3, the agreement between the methodology and the experts regarding the final classification of the entire vessel segments (including propagation). For this as said, we took 405 vessels labeled by experts to compare with the proposal. The results are presented for both cases, veins

Table 1: Confusion matrix of the A/V classification process.

	Experts Positive Arteries	Experts Negative Veins
System Positive Arteries	6504	752
System Negative Veins	961	6528

Table 2: Accuracy, specificity and sensitivity results in the A/V classification process.

Accuracy	Sensitivity	Specificity
88.38%	89.63%	87.16%

and arteries as well as the global result. We can verify that the global success rate is around 93%.

Table 3: Agreement between the methodology and the experts in the classification of vascular segments.

	Arteries	Veins	Total
Accuracy	186	191	377
Test set size	199	206	405
Success rate	93.46%	92.71%	93.08%

Despite that many approaches were tested in private image datasets, we compared the proposed methodology with other approaches of the state of the art. Table 4 depicts the results of this comparison, presenting the success rates that were obtained by each method, showing that the best performance was provided by our proposal.

4 DISCUSSION AND CONCLUSIONS

In this paper, we have developed a new computerized system for automatic retinal vasculature extraction and classification into arteries and veins using the near-infrared reflectance retinography that is provided by OCT scans. The proposed algorithm exploits the characteristics of each point of the vascular tree structure to classify the vessels. We use the k-means clustering technique with the feature vectors obtained from the extracted vessel profiles. The employed features consist of two components, the mean of the H component (from HSL color space) and the variance of the R component (from RGB color space).

Table 4: Vessel classification performance comparative between the techniques found in the literature and our proposal.

Method	Algorithm	Error Rate
Vázquez et al., 2013	k-means	89.80%
Dashtbozorg et al., 2014	LDA	88.30%
	QDA	87.40%
	KNN	70.00%
Yang et al., 2016	SVM	88.70%
Our method without Propagation	k-means	88.38%
Our method with Propagation	k-means	93.08%

The methodology was tested with 19 near-infrared reflectance retinographies included in 19 OCT patient scans. The method was trained with 5 images whereas the validation set included the rest of 14 images. From these images, 405 vessel segments and 14,745 vessel coordinates were identified and manually labeled by an expert clinician. As shown, the method offered promising results. Regarding the vessel coordinates, the method provided an accuracy of 88.38% as veins or arteries. In the case of vascular segments, the results obtained are around a 93%. The reason of this increase in the performance is the majority voting process (propagation) that discriminates each vessel into artery or vein. Finally, we made a comparison between various methods proposed in the literature. The obtained results show a correct result in comparison with the rest of the approaches.

Our study has some drawbacks. First, the differentiation of retinal vessels depends on the image quality. We can see that in the small vessels of the retina characteristics are similar to both clusters. This indicates the need of a study with a larger set of features. Secondly, this study does not consider the problems that normally appear at the intersections: crossings and bifurcations. These landmarks provide important information that can be used to construct a graph connecting the vessel segments. Increasing vascular structure would enhance the efficiency of the methodology mainly in the voting phase and propagation of classified points.

Despite of the promising results, there still exists some points that will be attempt as future works. First of all, we need to improve the phases of the method, in order to increase the success rates that were achieved. A greater set of features can be considered as well as testing other classifiers can increase the success rate. Future plans include development of automated methods for calculation the arterio-venous ratio (AVR). We validated the proposal with the near-

infrared reflectance retinographies that are provided in combination with the histological sections of the OCT images. Future versions of the methodology will combine the depth information of the histological sections to analyze the real layout, 3D, of the eye fundus. Ultimately, this methodology could be incorporated into a computer-aided system for detection of diabetic retinopathy, or other eye-related diseases.

ACKNOWLEDGEMENTS

This work is supported by the Instituto de Salud Carlos III, Government of Spain and FEDER funds of the European Union through the PI14/02161 and the DTS15/00153 research projects and by the Ministerio de Economía y Competitividad, Government of Spain through the DPI2015-69948-R research project.

REFERENCES

- Abu, A. (2008). Oct in diabetic dacular edema. *Acta Ophthalmologica*, 86.
- Blanco, M., Penedo, M. G., Barreira, N., Penas, M., and Carreira, M. J. (2006). Localization and extraction of the optic disc using the fuzzy circular hough transform. *Artificial Intelligence and Soft Computing*, pages 712–721.
- Brezinski, M. E. (2006). *Optical coherence tomography*. Elsevier Academic Press, Burlington, Mass.
- Caderno, I. G., Penedo, M. G., Barreira, N., Marino, C., and Gonzalez, F. (2005). Precise detection and measurement of the retina vascular tree. *Pattern Recognition and Image Analysis: Advances in Mathematical Theory and Applications*, 15:523–526.
- Calvo, D., Ortega, M., Penedo, M., and Rouco, J. (2011). Automatic detection and characterisation of retinal vessel tree bifurcations and crossovers in eye fundus images. *Computer Methods and Programs in Biomedicine*, 103:28–38.
- Cordero, A. (2011). Scientific realism and the divide et impera strategy: The ether saga revisited. *Philosophy of Science*, 78(5):1120–1130.
- Dashtbozorg, B., Mendonca, Maria, A., and Campilho, A. (2014). An automatic graph-based approach for artery/vein classification in retinal images. *IEEE Transactions on Image Processing*, 23:1073–1083.
- Duker, J. S., Waheed, N. K., and Goldman, D. (2014). *Handbook of retinal OCT*.
- Grisan, E. and Ruggeri, A. (2003). A divide et impera strategy for automatic classification of retinal vessels into arteries and veins. *Engineering in Medicine and Biology Society*, 1:890–893.
- Joshi, V. S., Reinhardt, J. M., Garvin, M. K., and Abramoff, M. D. (2014). Automated method for identification and artery-venous classification of vessel trees in retinal vessel networks. *PLoS ONE*, 9(2).
- Kondermann, C., Kondermann, D., and Yan, M. (2007). Blood vessel classification into arteries and veins in retinal images. *Proc. SPIE*, 6512.
- Pascolini, DonatellaMariotti, S. P. (2011). Global estimates of visual impairment: 2010. *British Journal of Ophthalmology*, 96(5):614–618.
- Vázquez, S. G., Cancela, B., Barreira, N., Penedo, M. G., Rodríguez-Blanco, M., Pena Seijo, M., de Tuero, G. C., Barceló, M. A., and Saez, M. (2013). Improving retinal artery and vein classification by means of a minimal path approach. *Machine Vision and Applications*, 24(5):919–930.
- Whiting, D. R., Guariguata, L., Weil, C., and Shaw, J. (2011). Idf diabetes atlas: Global estimates of the prevalence of diabetes for 2011 and 2030. *Diabetes Research and Clinical Practice*, 94(3):311–321.
- Wong, T. Y. (2005). Retinal arteriolar narrowing, hypertension, and subsequent risk of diabetes mellitus. *Arch Intern Med*, 165(9):1060.
- Yang, Y., Bu, W., Wang, K., Zheng, Y., and Wu, X. (2016). Automated artery-vein classification in fundus color images. *Communications in Computer and Information Science*, 623:228–237.