

Extended Abstract

Fluid Region Analysis and Identification via Optical Coherence Tomography Image Samples [†]

Plácido L. Vidal ^{1,2,*}, Joaquim de Moura ^{1,2}, Jorge Novo ^{1,2}, José Rouco ^{1,2} and Marcos Ortega ^{1,2}

¹ Department of Computer Science, University of A Coruña, 15071 A Coruña, Spain;

joaquim.demoura@udc.es (J.d.M.); jnov@udc.es (J.N.); jrrouco@udc.es (J.R.); mortega@udc.es (M.O.)

² CITIC-Research Center of Information and Communication Technologies, University of A Coruña, 15071 A Coruña, Spain

* Correspondence: placido.francisco.lizancos.vidal@udc.es; Tel.: +34-881-01-13-30

† Presented at the XoveTIC Congress, A Coruña, Spain, 27–28 September 2018.

Published: 17 September 2018

Abstract: The work herein proposed presents a methodology which aims to identify cystoid regions using OCT scans. This method obtained satisfactory results detecting cystoid regions with different levels of complexity without needing any preprocessing nor candidate filtering steps.

Keywords: computer-aided diagnosis; retinal imaging; optical coherence tomography; intraretinal cystoid region characterization; feature selection; classification

1. Introduction

Optical Coherence Tomography (OCT) is a non-invasive medical imaging modality that provides morphological information about the retinal tissues. This information is commonly used in the early diagnosis and analysis of patients with potential eye and systemic diseases as, for reference, Diabetic Retinopathy (DR), Diabetic Macular Edema (DME) and Age-related Macular Degeneration (AMD), three of the leading causes of blindness in adults of working age in developed countries. Given the global relevance of this topic, an accurate identification of any present cystoid region is crucial to perform an adequate diagnosis, treatment, prevention and rehabilitation.

2. Methodology

In this work, we propose a novel methodology for the automatic identification and characterization of the intraretinal cystoid fluid regions using OCT images [1]. To achieve this, we analyzed a complete and heterogeneous set of 326 intensity and texture descriptors. The most relevant features were selected using the Relief-F and L0 feature selectors and tested with the Linear Discriminant Classifier, the Quadratic Discriminant Classifier and k Nearest Neighbors with $k = 5$.

3. Results

The proposed methodology was tested using 51 OCT images obtained with a CIRRUS© HD-OCT confocal laser ophthalmoscope (Carl Zeiss Meditec, Inc., Dublin, California). From these images, a total of 723 samples from cystoid and non-cystoid regions were extracted, using a sample size of 51×51 . This sample size was empirically determined to be large enough to detect both big and small cystoid bodies in the retinal layers.

The methodology correctly identified the intraretinal cystoid fluid regions with a satisfactory accuracy of 90.6%. As shown in Figure 1, both fluid regions and non-cystoid regions are detected by the system despite the multiple complications.

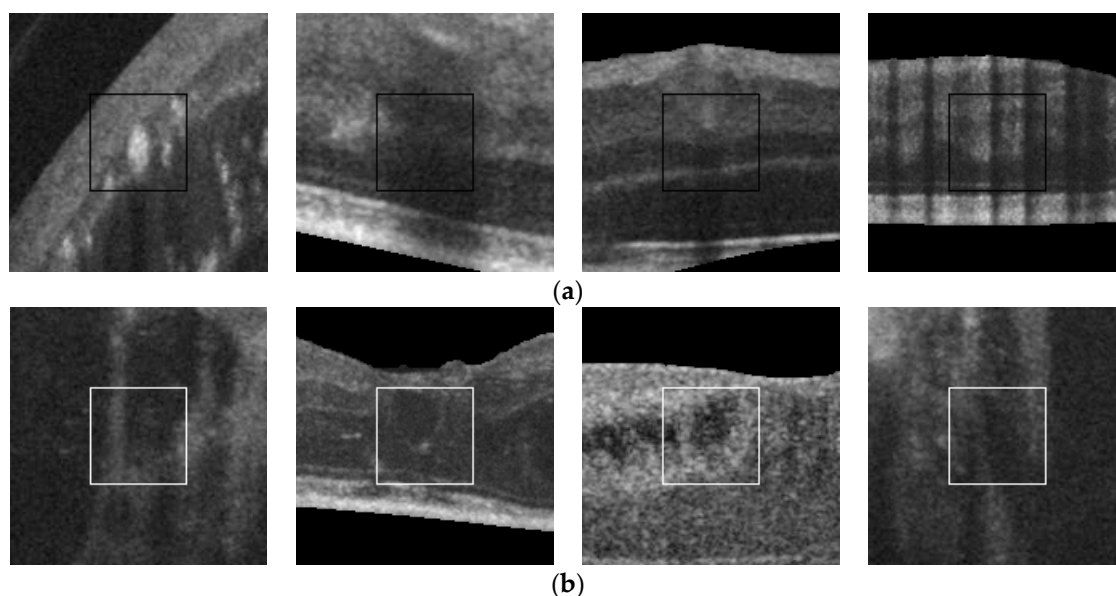


Figure 1. Results obtained with different levels of complexity. (a) Non-cystoid regions; (b) Cystoid regions.

Author Contributions: All authors contributed equally.

Acknowledgments: This work is supported by the Instituto de Salud Carlos, III, Government of Spain and FEDER funds of the European Union through the PI14/02161 and the DTS15/00153 research projects and by the Ministerio de Economía y Competitividad, Government of Spain through the DPI2015-69948-R research project.

Conflicts of Interest: The authors declare no conflict of interest. The founding sponsors had no role in the design of the study; in the collection, analyses, or interpretation of data; in the writing of the manuscript, and in the decision to publish the results.

Reference

1. De Moura, J.; Vidal, P.L.; Novo, J.; Rouco, J.; Ortega, M. Feature definition, analysis and selection for cystoid region characterization in optical coherence tomography. *Procedia Comput. Sci.* **2017**, *112*, 1369–1377, doi:10.1016/j.procs.2017.08.043.



© 2018 by the authors. Licensee MDPI, Basel, Switzerland. This article is an open access article distributed under the terms and conditions of the Creative Commons Attribution (CC BY) license (<http://creativecommons.org/licenses/by/4.0/>).