

Extended Abstract

Automatic System for the Identification and Visualization of the Retinal Vessel Tree Using OCT Imaging [†]

Joaquim de Moura ^{1,2,*}, Jorge Novo ^{1,2}, Noelia Barreira ^{1,2}, Manuel G. Penedo ^{1,2} and Marcos Ortega ^{1,2}

¹ Department of Computing, University of A Coruña, 15071 A Coruña, Spain; jnovo@udc.es (J.N.); nbarreira@udc.es (N.B.); mgpenedo@udc.es (M.G.P.); mortega@udc.es (M.O.)

² CITIC-Research Center of Information and Communication Technologies, University of A Coruña, 15071 A Coruña, Spain

* Correspondence: joaquim.demoura@udc.es; Tel.: +34-981-167-000

† Presented at the XoveTIC Congress, A Coruña, Spain, 27–28 September 2018.

Published: 17 September 2018

Abstract: This paper proposes a system for the three-dimensional identification and visualization of the retinal vasculature using Optical Coherence Tomography (OCT) scans. This fully automatic tool provides useful biomarkers to the medical specialists that facilitate the prevention, diagnosis and treatment of various retinal and systemic pathologies.

Keywords: computer-aided diagnosis; Retinal imaging; Optical Coherence Tomography; vasculature; Retinal microcirculation

1. Introduction

The eye fundus is the only part of the human body where the blood vessels can be directly visualized non-invasively and safely in real time. An accurate analysis of the morphology of the retinal microvasculature allows the early diagnosis of different systemic diseases that can affect multiple parts of the body, such as hypertension, diabetes or arteriosclerosis, all of which are leading global public health concerns.

Nowadays, Optical Coherence Tomography (OCT) technique is increasing its use in clinical studies, health service research and daily clinical practice. This biomedical imaging system is capable of providing high-resolution cross-sectional scans of the internal microstructure of different retinal tissues in real time. These OCT scans allow the medical specialists to analyze and identify anatomical and physiological changes in the complex microvascular network of the retina.

In this work, we propose the development of a novel and complete methodology for the automatic identification and three-dimensional visualization of the retinal vasculature using OCT scans. This fully automatic system provides an intuitive visualization tool that facilitates a more complete and reliable analysis of the complex vascular structure of the retina.

2. Methodology

The proposed methodology is divided into four main steps: a first step, where we extract the two-dimensional vessel tree in the NIR retinography image; second, we estimate the vessel calibers; third, we obtain the corresponding depth of the vessel profiles in the OCT sections; and a final fourth step, where we make a complete three-dimensional representation of the retinal vasculature. This system allows the manipulation of the retinal vessel tree by means of graphical transformations including translation, scaling and rotation and their arbitrary combinations [1].

3. Results and Conclusions

The proposed method reached satisfactory results, providing a consistent and coherent three-dimensional retinal vessel tree reconstruction and visualization that can be posteriorly used in different medical analysis and diagnostic processes of various retinal and systemic pathologies. Figure 1 shows a representative example of the three-dimensional reconstruction and visualization where the caliber scale bar is also presented in the screen to facilitate the analysis of the medical specialists.

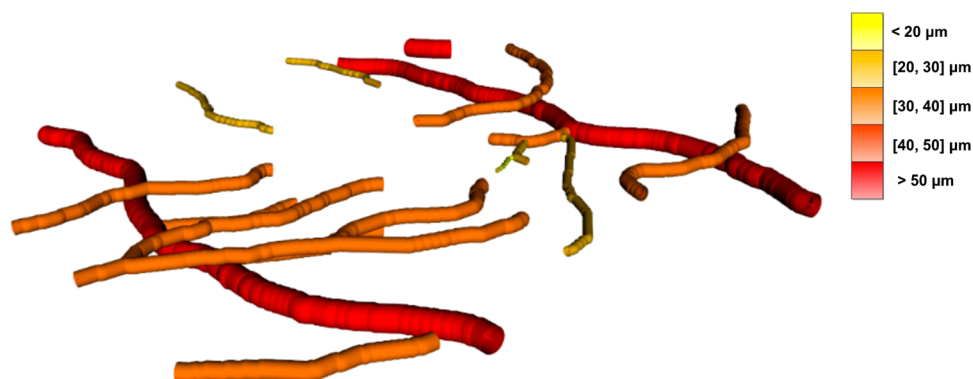


Figure 1. Representative example of the three-dimensional reconstruction and visualization of the retinal vessel tree using OCT images. Note the caliber scale bar that facilitates the analysis of the specialist.

Author Contributions: J.d.M., J.N. and N.B. contributed to the analysis and design of the computer methods and the experimental evaluation methods. M.G.P. and M.O. contributed with domain-specific knowledge. All the authors performed the result analysis. J.d.M. was in charge of writing the manuscript, and all the authors participated in its critical revision and final approval.

Acknowledgments: This work is supported by the Instituto de Salud Carlos III, Government of Spain and FEDER funds of the European Union through the PI14/02161 and the DTS15/00153 research projects and by the Ministerio de Economía y Competitividad, Government of Spain through the DPI2015-69948-R research project. Also, this work has received financial support from the European Union (European Regional Development Fund-ERDF) and the Xunta de Galicia, Centro singular de investigación de Galicia accreditation 2016-2019, Ref. ED431G/01; and Grupos de Referencia Competitiva, Ref. ED431C 2016-047.

Conflicts of Interest: The authors declare no conflict of interest. The founding sponsors had no role in the design of the study; in the collection, analyses, or interpretation of data; in the writing of the manuscript, and in the decision to publish the results.

References

1. De Moura, J.; Novo, J.; Charlón, P.; Barreira, N.; Ortega, M. Enhanced visualization of the retinal vasculature using depth information in OCT. *Med. Biol. Eng. Comput.* **2017**, *55*, 2209–2225.



© 2018 by the authors. Licensee MDPI, Basel, Switzerland. This article is an open access article distributed under the terms and conditions of the Creative Commons Attribution (CC BY) license (<http://creativecommons.org/licenses/by/4.0/>).