



## Choroid segmentation in non-EDI OCT images of multiple sclerosis patients\*

Emilio López-Varela<sup>1,2</sup>, Noelia Barreira<sup>1,2</sup>, Nuria Olivier Pascual<sup>3</sup>, Emma Garcia Ben<sup>3</sup>, Sara Rubio Cid<sup>3</sup>, and Manuel G. Penedo<sup>1,2</sup>

<sup>1</sup> Centro de investigación CITIC, Universidade da Coruña, 15071 A Coruña, Spain

<sup>2</sup> Grupo VARPA, Instituto de Investigación Biomédica de A Coruña (INIBIC), Universidade da Coruña, Xubias de Arriba, 84, 15006 A Coruña, Spain

<sup>3</sup> Servizo de Oftalmoloxía, Complejo Hospitalario Universitario de Ferrol (CHUF), Av. da Residencia S/N, Ferrol 15405, Spain

### Abstract

Optical coherence tomography (OCT) is a non-invasive diagnostic technique that can image ocular structures. Recently, this imaging technique has been used to diagnose and monitor patients with multiple sclerosis (MS), as several clinical studies have linked the development of MS to various changes in the eye. Among the different structures, one of the relevant biomarkers for MS analysis is the choroid. Systems such as Enhanced Depth Imaging (EDI) provide detailed images of the choroid region. However, OCT images are not routinely captured using this technology unless the study is specifically focused on choroidal analysis. In this work we propose a robust approach, based on convolutional neural networks to segment the choroid in non-EDI OCT images. The results obtained show that the proposed network manages to delimit the inferior contour of the choroid in a similar way to the experts.

## 1 Introduction

Optical coherence tomography (OCT) is a non-invasive diagnostic technique that can image ocular structures with semi-histological resolution [3]. Recently, this imaging technique has been used to diagnose and monitor patients with multiple sclerosis (MS), as several clinical studies have linked the development of MS to various changes in the eye [1]. This disease is the leading cause of non-traumatic neurological disability in young adults, so early diagnosis and

---

\*This research was funded by Instituto de Salud Carlos III, Government of Spain, DTS18/00136 research project; Ministerio de Ciencia e Innovación y Universidades, Government of Spain, RTI2018-095894-B-I00 research project; Ministerio de Ciencia e Innovación, Government of Spain through the research project with reference PID2019-108435RB-I00; Consellería de Cultura, Educación e Universidade, Xunta de Galicia, Grupos de Referencia Competitiva, grant ref. ED431C 2020/24; Axencia Galega de Innovación (GAIN), Xunta de Galicia, grant ref. IN845D 2020/38; CITIC, Centro de Investigación de Galicia ref. ED431G 2019/01, receives financial support from Consellería de Educación, Universidade e Formación Profesional, Xunta de Galicia, through the ERDF (80%) and Secretaría Xeral de Universidades (20%). Emilio López Varela acknowledges its support under FPI Grant Program through PID2019-108435RB-I00 project.

appropriate follow-up are essential. Among the ocular structures, one of the most relevant to carry out this follow-up is the choroid, a tissue that provides nutrition to the retinal layers and undergoes different morphological changes as the disease progresses. Systems such as Enhanced Depth Imaging (EDI) provide detailed images of the choroid region so several studies have proposed segmenting the choroid using this type of imaging [4]. However, OCT images are not routinely captured using this technology unless the study is specifically focused on choroidal analysis. Taking these factors into account, in this work we propose a robust convolutional neural network based approach to segment the choroid in non-EDI OCT images. To test both the robustness and efficiency of our method, we performed experiments on a set of non-EDI images captured with various settings in healthy and MS patients.

## 2 Materials and Methods

A dataset consisting of a total of 224 images of healthy and MS patients obtained with different configurations at the Complejo Hospitalario Universitario de Ferrol was used. This dataset was divided into two groups. On the one hand, a group of 196 images was used to train the model. Each of these images has an associated segmentation mask where the choroid was manually labelled by an expert. On the other hand, the remaining 28 images were labelled by three different medical experts. Each expert labelled the inferior choroidal contour in each of the images twice. The first time, the experts used the original images to perform the labelling, while the second time they used the images after applying local contrast enhancement. This results in a total of six edge labels for each image. This set of 28 images serves to validate whether there are differences between the segmentation performed by our network and that performed by the different medical experts, as well as to see how much variability there is in the labelling performed by the medical experts.

To carry out the choroid segmentation, we use a feature pyramid network (FPN) [2] adapted to a semantic segmentation task. This type of architecture allows feature maps to be extracted at different scales, which are used together to perform the final model prediction. The feature maps obtained at different scales allow a more accurate segmentation of the different objects and their boundaries. A DenseNet201 was used as the encoder for our network, as this encoder is powerful enough to extract feature maps with all the necessary information to segment the choroid into images with different textures and noises.

## 3 Results and Discussion

We compared the Euclidean distance (EUC) between the lower boundaries detected by each subject (the network and the experts) in three different ways. First, we calculated the EUC between the contours delimited by each subject in the original OCT images and the contours inferred by the same subject in the enhanced images. This allows us to check whether the network behaves like the experts in both kind of images. The EUC per image was  $16.24 \pm 11.99$  px and  $13.98 \pm 7.66$  px in the case of the network and the best expert, respectively. Second, we calculate the EUC between the contours marked by each subject and the average contours in the original images. The average contours are computed by averaging the labelling of the three human experts. An EUC per image of  $14.02 \pm 8.72$  px was obtained by the network and  $15.55 \pm 12.70$  px, by the best expert. Finally, we repeat the last experiment in the contrast-enhanced images. In this case, the network got an EUC per image of  $16.55 \pm 8.11$  px while the results of the best expert were  $14.44 \pm 9.14$  px. Figure 1 shows the distribution of the

EUC obtained per expert for each of these three measures. To improve the visualisation, the distances were normalised to the range (0, 1). There is some variability among medical experts in the delineation of the inferior choroidal contour because this contour is often diffuse. The box plots show that there are no significant differences among the network and the experts. In addition, Figure 2 shows an example that compares the lower bound predicted by our network versus all the manual labellings.

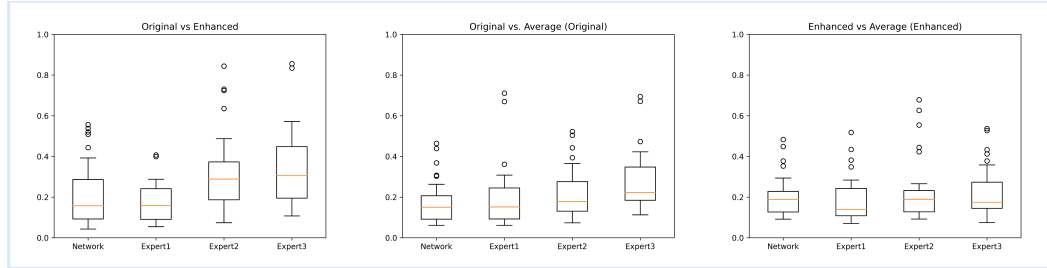


Figure 1: From left to right: EUC distribution in the original images vs. the enhanced images, EUC distribution in the original images vs. the average labelling on the original images and EUC distribution in the enhanced images vs. the average labelling on the enhanced images.

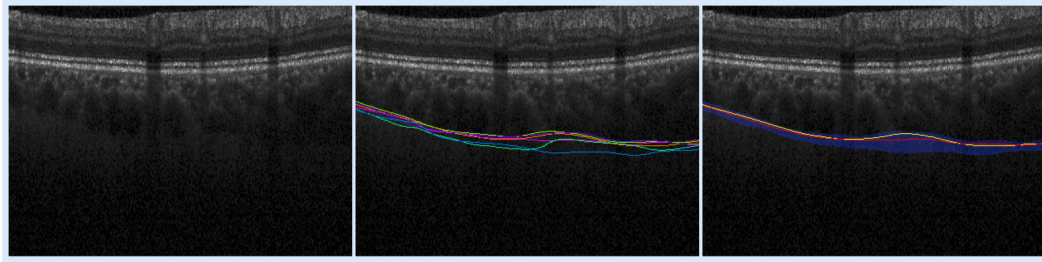


Figure 2: Left: Original image. Center: Contours delimited by all the experts. Right: Contour defined by the network (yellow) and average manual contour (red) over the area of dispersion of the experts' contours (blue).

Specifically, our network has a very accurate performance when using the original images and a performance comparable to the best of the experts when using the contrast-enhanced images. This expert has more years of experience in this field than the other experts so her labellings are more consistent. We can also observe that expert three shows the higher variability and tends to overestimate the contour of the choroid. The variability of our approach is slightly higher than the most consistent expert but in the range of the other experts so we can conclude that the proposed network behaves like an expert in this task.

## References

- [1] Josefine Britze and Jette Laurup Frederiksen. Optical coherence tomography in multiple sclerosis. *Eye*, 32(5):884–888, 2018.

- [2] Tsung-Yi Lin, Piotr Dollár, Ross Girshick, Kaiming He, Bharath Hariharan, and Serge Belongie. Feature pyramid networks for object detection. In *Proceedings of the IEEE conference on computer vision and pattern recognition*, pages 2117–2125, 2017.
- [3] Emilio López-Varela, Plácido L Vidal, Nuria Olivier Pascual, Jorge Novo, and Marcos Ortega. Fully-automatic 3d intuitive visualization of age-related macular degeneration fluid accumulations in oct cubes. *Journal of Digital Imaging*, pages 1–12, 2022.
- [4] Bahareh Salafian, Rahele Kafieh, Abdolreza Rashno, Mohsen Pourazizi, and Saeid Sadri. Automatic segmentation of choroid layer in edi oct images using graph theory in neutrosophic space. *arXiv preprint arXiv:1812.01989*, 2018.