

# Intraretinal Fluid Detection by Means of a Densely Connected Convolutional Neural Network Using Optical Coherence Tomography Images <sup>†</sup>

Plácido L. Vidal <sup>1,2,\*</sup> , Joaquim de Moura <sup>1,2</sup> , Jorge Novo <sup>1,2</sup>  and Marcos Ortega <sup>1,2</sup> 

<sup>1</sup> Department of Computer Science, University of A Coruña, 15071 A Coruña, Spain

<sup>2</sup> CITIC-Research Center of Information and Communication Technologies, University of A Coruña, 15071 A Coruña, Spain

\* Correspondence: placido.francisco.lizancos.vidal@udc.es; Tel.: +34-981-16-70-00 (ext. 1330)

† Presented at the 2nd XoveTIC Conference, A Coruña, Spain, 5–6 September 2019.

Published: 1 August 2019



**Abstract:** Hereby we present a methodology with the objective of detecting retinal fluid accumulations in between the retinal layers. The methodology uses a robust Densely Connected Neural Network to classify thousands of subsamples, extracted from a given Optical Coherence Tomography image. Posteriorly, using the detected regions, it satisfactorily generates a coherent and intuitive confidence map by means of a voting strategy.

**Keywords:** Computer-Aided Diagnosis; retinal imaging; Optical Coherence Tomography; deep learning; DenseNet; intraretinal cystoid region characterization

## 1. Introduction

A macular edema consists in a swelling of the macula caused by the accumulation of pathological fluid in between the retinal tissues. This disease corresponds to one of the main causes of blindness in developed countries, as its main triggers are related to an increasing lifespan and the lifestyle of the afflicted. To study, diagnose and treat these fluid accumulations, clinicians typically use Optical Coherence Tomography (OCT) images. This non-invasive medical imaging technique allows to generate a representation of the retina with a resolution of microns.

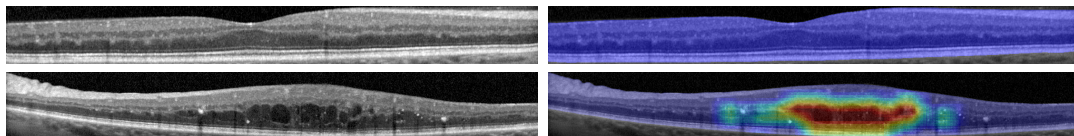
To date, this diagnostic is mostly done by means of a visual inspection by the expert ophthalmologist, prone to subjective factors. Thus, and given the relevance of the aforementioned pathologies, an automated methodology to facilitate the inspection is desirable.

## 2. Methodology

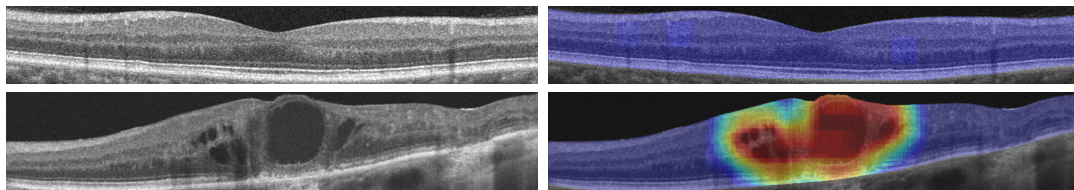
To solve this issue, we merged a regional analysis strategy that has proven to be resilient in the identification of fluid regions [1], a visualization technique specially designed to offer satisfactory results even when facing the most challenging conditions [2] and an artificial neural network architecture specially designed to overcome overfitting thanks to its densely connected layers, adding capabilities of self-supervision [3]. Thus, to generate the pathological confidence maps, the images are thoroughly sampled, extracting thousands of samples from them. Afterwards, using a previously trained DenseNet, these samples are classified and used as ballots to determine the confidence of the different regions in the image.

### 3. Results

The network was trained using a base dataset of 3247 samples from two different representative OCT capture devices, increased by means of data augmentation. Additionally, the training of the network was done by using an automated control of the learning rate depending on the validation results, and stopped by means of an early-stopping criteria that detects when the training quality has stagnated. To further study the capabilities of our system, the training process was repeated 50 times, randomly distributing the training and validation datasets and recalculating the data augmentation procedure. After all the repetitions, the system attained a satisfactory mean test accuracy of  $97.45\% \pm 0.7611$  and a mean area under the ROC curve (AUC) of  $0.9961 \pm 0.0029$ . Regarding maps, as shown in Figures 1 and 2, the DenseNet architecture is able to successfully represent both pathological and healthy regions in different representative devices of the domain.



**Figure 1.** Results from a Spectralis OCT device from Heidelberg Engineering, including a healthy and a pathological example.



**Figure 2.** Results from a Cirrus HD-OCT device from Carl Zeiss Meditec, including a healthy and a pathological example.

**Author Contributions:** P.L.V. and J.d.M. designed and performed the experiments. J.N. and M.O. contributed with their domain knowledge. All the authors helped with the analysis of the results and revision of the manuscript, written by P.L.V.

**Funding:** This research was funded by Instituto de Salud Carlos III grant number DTS18/00136, Ministerio de Economía y Competitividad grant number DPI 2015-69948-R, Xunta de Galicia through the accreditation of Centro Singular de Investigación 2016–2019, Ref. ED431G/01, Xunta de Galicia through Grupos de Referencia Competitiva, Ref. ED431C 2016-047 and Xunta de Galicia predoctoral grant contract ref. ED481A-2019/196.

**Conflicts of Interest:** The authors declare no conflict of interest.

### References

1. de Moura, J.; Vidal, P.L.; Novo, J.; Rouco, J.; Ortega, M. Feature Definition, Analysis and Selection for Cystoid Region Characterization in Optical Coherence Tomography. In *Knowledge-Based and Intelligent Information & Engineering Systems, Proceedings of the 21st International Conference KES-2017, Marseille, France, 6–8 September 2017*; Elsevier: Amsterdam, The Netherlands, 2017; pp. 1369–1377. Available online: <https://www.sciencedirect.com/science/article/pii/S1877050917313844> (accessed on 31 July 2019)
2. Vidal, P.L.; de Moura, J.; Novo, J.; Penedo, M.G.; Ortega, M. Intraretinal fluid identification via enhanced maps using optical coherence tomography images. *Biomed. Opt. Express* **2018**, *9*, pp. 4730–4754.
3. Vidal, P.L.; de Moura, J.; Novo, J.; Rouco, J.; Ortega, M. Cystoid Fluid Color Map Generation in Optical Coherence Tomography Images Using a Densely Connected Convolutional Neural Network. In *Proceedings of the 2019 International Joint Conference on Neural Networks, Budapest, Hungary, 14–19 July 2019*.

